

# Regionally Localized Thinning of the Cerebral Cortex in Schizophrenia

Gina R. Kuperberg, MD, PhD, MRCPsych; Matthew R. Broome, MB, ChB, MRCPsych; Philip K. McGuire, MD, PhD, MRCPsych; Anthony S. David, MD, FRCPSych; Marianna Eddy, BA; Fujiro Ozawa, MD, PhD; Donald Goff, MD; W. Caroline West, PhD; Steven C. R. Williams, PhD; Andre J. W. van der Kouwe, PhD; David H. Salat, PhD; Anders M. Dale, PhD; Bruce Fischl, PhD

**Background:** Schizophrenia is characterized by small reductions in cortical gray matter volume, particularly in the temporal and prefrontal cortices. The question of whether cortical thickness is reduced in schizophrenia has not been addressed using magnetic resonance imaging (MRI) techniques. Our objectives were to test the hypothesis that cortical thinning in patients with schizophrenia (relative to control subjects) is greater in temporal and prefrontal regions of interest (ROIs) than in control ROIs (superior parietal, calcarine, postcentral, central, and precentral cortices), and to obtain an unbiased estimate of the distribution of cortical thinning in patients (relative to controls) by constructing mean and statistical cortical thickness difference maps.

**Methods:** Participants included 33 right-handed outpatients receiving medication and meeting DSM-IV criteria for schizophrenia and 32 healthy volunteers, matched on age and parental socioeconomic status. After high-resolution MRI scans, models of the gray-white and pial surfaces were generated for each individual's cortex, and the distance between these 2 surfaces was used to compute cortical thickness. A surface-based averaging technique that aligned the main cortical folds across indi-

viduals allowed between-group comparisons of thickness within ROIs, and at multiple, uniformly sampled loci across the cortical ribbon.

**Results:** Relative to controls, patients showed greater cortical thinning in temporal-prefrontal ROIs than in control ROIs, as revealed by a significant ( $P < .009$ ) interaction between group and region type. Cortical thickness difference maps revealed significant (at  $P < .05$ , corrected) thinning within the orbitofrontal cortices bilaterally; the inferior frontal, inferior temporal, and occipitotemporal cortices on the left; and within the medial temporal and medial frontal cortices on the right. Superior parietal and primary somatosensory and motor cortices were relatively spared, even at subthreshold significance levels.

**Conclusions:** Patients with chronic schizophrenia showed widespread cortical thinning that particularly affected the prefrontal and temporal cortices. This thinning might reflect underlying neuropathological abnormalities in cortical structure.

*Arch Gen Psychiatry.* 2003;60:878-888

From the Department of Psychiatry, Massachusetts General Hospital (Drs Kuperberg and Goff), and the Athinoula A. Martinos Center for Biomedical Imaging (Drs Kuperberg, Ozawa, van der Kouwe, Salat, Dale, and Fischl), Charlestown, Mass; the Section of Neuroimaging, Division of Psychological Medicine (Drs Broome, McGuire, and David), and the Department of Neurology (Dr Williams), Institute of Psychiatry, London, England; and the Department of Neurology, Massachusetts General Hospital, Boston (Ms Eddy and Dr West).

SCHIZOPHRENIA IS characterized by subtle but significant gray matter deficits, particularly affecting the prefrontal and temporal cortices.<sup>1</sup> Morphometric studies have focused on the measurement of cortical volume. The human cerebral cortex, however, is a 6-layered sheet of neural tissue that has been extensively folded, such that approximately two thirds is buried within cortical sulci. We identified sites of cortical thinning in schizophrenia using an automated morphometric method that yields measures of cortical gray matter thickness.

Morphometric studies examining cortical volume in schizophrenia have traditionally focused on regions of interest (ROIs) that are selected on the basis of a

priori hypotheses. Although ROI studies have the advantage of being theoretically motivated, they are labor-intensive and time-consuming, and therefore usually do not examine the whole brain (with few exceptions, eg, Goldstein et al<sup>2</sup>). To complement the ROI approach, there have been attempts to automate the measurement of gray matter volume or density throughout the brain.<sup>3-6</sup> So that homologous regions can be averaged within and between subject groups, individual brains must be aligned, by registering to standardized volumetric space<sup>3,4,7</sup> or by using computational matching strategies that align corresponding locations on the cortical surface.<sup>5,6</sup> Maps showing mean and statistical differences in volume or density between groups can then be constructed. This approach

(hereafter termed the *morphometric brainmap* approach) has the advantage of giving an unbiased and comprehensive assessment of morphometric changes at uniformly sampled loci throughout the brain. Taken together, morphometric brainmap studies in schizophrenia have confirmed subtle volumetric reductions in multiple anatomical regions within the prefrontal and temporal cortices<sup>1,8-10</sup> and within other regions such as the insula,<sup>8-10</sup> the occipitotemporal cortex,<sup>10</sup> and, in patients with early-onset schizophrenia, the parietal cortex.<sup>5</sup> This picture of subtle, widespread morphometric changes is consistent with a growing understanding of schizophrenia as a disorder characterized by cognitive abnormalities in a number of domains, with associated functional abnormalities that affect multiple neural systems, particularly in the prefrontal and temporal cortices.<sup>11</sup>

The question of whether cortical thickness is reduced in patients with schizophrenia has, thus far, not been addressed using magnetic resonance imaging (MRI) techniques. This is an important question because abnormalities in cortical thickness might reflect underlying neuropathological abnormalities in the intrinsic structure and integrity of cortical laminae.<sup>12,13</sup> Some postmortem studies in schizophrenia report modest thinning of the cortical ribbon and/or layer-specific decreases in cell density in localized regions, such as within the dorsolateral prefrontal cortex.<sup>14-16</sup> Manual postmortem measurements of thickness across the entire cortical surface on large numbers of individuals, however, would be too time-consuming to be feasible. Similarly, it would also be extremely time-consuming and technically very difficult to measure thickness manually across the cortical surface from slice MR data.<sup>17</sup>

In the present study, we used automated, objective methods<sup>17-21</sup> to address the question of whether the thickness of the cortical gray matter is reduced in patients with schizophrenia and, if so, to determine the regional distribution of such thinning. Volume is a product of thickness and surface area. Hence, we predicted that cortical thinning might contribute to the volumetric changes in temporal and prefrontal cortices described in previous morphometric studies of schizophrenia. We computed the average cortical thickness in several ROIs in individual subjects to test our specific hypothesis that thinning would be greater in patients (relative to control subjects) in temporal and prefrontal ROIs than in control ROIs (the superior parietal cortex and primary visual, somatosensory, and motor cortices). In addition, we adopted a morphometric brainmap approach by constructing cortical thickness difference maps that gave an unbiased estimate of mean and statistical differences in thickness between patients and controls at multiple, uniformly sampled loci across the entire cortical ribbon.

## METHODS

### PARTICIPANTS

Thirty-three subjects (17 patients and 16 matched controls [data set 1]) underwent scanning on a 1.5-T GE Signa NV/i system scanner (General Electric Company, Milwaukee, Wis),

**Table 1. Demographic and Psychopathological Data of Healthy Control Subjects and Patients With Schizophrenia\***

Parameter	Subject Group	
	Controls (n = 32)	Patients (n = 32)
Sex, No. M/F	26/6	27/5
Race, No. white/African American/ Afro-Caribbean/Hispanic	26/3/2/1	20/6/6/0
Age, y	39 (11)	40 (10)
Education, y†	14 (2)	12 (1)
Hollingshead Index score‡	2.8 (1)	3.1 (1)
Premorbid verbal IQ§	116 (9)	108 (10)
Anticholinergics, No. receiving/ not receiving	NA	1/15
Chlorpromazine equivalents	NA	511 (336)
Duration of illness, y	NA	16 (10)
PANSS global score	NA	63.4 (14.7)
PANSS positive score	NA	13.7 (5.0)
PANSS negative score	NA	18.8 (5.2)

Abbreviations: NA, not applicable; PANSS, Positive and Negative Syndrome Scale.<sup>29</sup>

\*Data sets 1 and 2 are combined. Patients and controls matched closely in sex, and there was no significant difference between the groups in age ( $P = .84$ ). Unless otherwise indicated, data are expressed as mean (SD).

†Patients had 1 year less education than controls ( $P < .005$ ).

‡No significant difference was found between groups for parental socioeconomic status ( $P = .32$ ), as assessed by the Hollingshead Two-Factor Index of Social Position.<sup>28</sup>

§Patients had a slightly lower premorbid IQ ( $P < .001$ ), as assessed by the National Adult Reading Test<sup>26</sup> or the North American Reading Test.<sup>27</sup>

and an additional 32 subjects (16 patients and 16 matched controls [data set 2]) underwent scanning on a 1.5-T Siemens scanner (Siemens Medical Solutions, Iselin, NJ). Twenty-four subjects from data set 1 were recruited in London, England (12 patients from the Maudsley and Bethlem Royal Hospitals and 12 controls by advertisement); the remaining 9 subjects of data set 1 were recruited in Boston, Mass (5 patients from the Erich Lindemann Mental Health Center in Massachusetts, and 4 controls by advertisement). One subject from data set 1 was subsequently excluded, leaving 32 subjects (16 patients and 16 matched controls) in data set 1. All subjects in data set 2 were recruited in Boston (16 patients from the Erich Lindemann Mental Health Center and 16 controls by advertisement). All participants were right-handed as assessed using the modified Edinburgh Handedness Inventory<sup>22,23</sup> and were aged 19 to 63 years. Exclusion criteria for all participants included neurological disease or damage, head trauma with documented cognitive sequelae or loss of consciousness of more than 5 minutes, medical disorders that can impair neurocognitive function, a history of substance abuse or dependence, and specific exclusions for MRI. Written consent was obtained from all subjects before participation according to the established guidelines of the Maudsley and Bethlem Royal Hospitals and Massachusetts General Hospital human subjects research committees.

Diagnoses were made by staff psychiatrists and were confirmed by 2 psychiatrists (G.R.K. and M.R.B.) using a structured clinical interview<sup>24</sup> and examination of the case notes. All patients met DSM-IV criteria for schizophrenia<sup>25</sup> and were receiving stable doses of antipsychotic medication. One patient was taking anticholinergic medication (psychopathological details are shown in **Table 1**). Healthy volunteers were not taking any medication and were screened<sup>24</sup> to exclude the presence of psychiatric disorders. Patients and controls matched closely on demographic characteristics (Table 1).

## MRI ACQUISITION

Subjects in data set 1 underwent 2 structural scans on a 1.5-T GE Signa NV/i System at the Maudsley Hospital, London, or the Athinoula A. Martinos Center for Biomedical Imaging, Charlestown, Mass. Each scan consisted of a radiofrequency spoiled gradient refocused acquisition in the steady state [rf-spoiled GRASS] sequence with 124 sagittal slices; 1.3-mm thickness; repetition time (TR), 24 milliseconds; echo time (TE), minimum for symmetric echo; flip angle, 30°; bandwidth, 16 kHz and in-plane resolution, 1.3 × 1 mm. Scanning sequences and protocols were identical in the 2 sites.

Subjects in data set 2 underwent 2 structural scans on a 1.5-T Siemens scanner at the Athinoula A. Martinos Center for Biomedical Imaging, Boston. Each scan consisted of a 3-dimensional magnetization prepared rapid acquisition gradient-echo (3-D MPRAGE) sequence (128 sagittal slices; 1.3-mm thickness; TR, 7.25 milliseconds; TE, 3 milliseconds; flip angle, 7°; bandwidth, 195 Hz per pixel; in-plane resolution, 1.3 × 1 mm).

## DATA ANALYSIS

### Measurement of Cortical Thickness in Individual Subjects

The 2 structural scans for each participant were averaged, after motion correction, to create a single high signal-to-noise average volume, thus avoiding confounds of poor scan quality or low signal. The resulting volume was used to segment cerebral white matter<sup>18,19</sup> and to estimate the gray-white interface. Topological defects in the gray-white estimate were fixed,<sup>21</sup> and this gray-white estimate was used as the starting point for a deformable surface algorithm designed to find the pial surface with submillimeter precision.<sup>17</sup> The entire cortex in each individual subject was then visually inspected, and any inaccuracies in segmentation were manually corrected. One subject's data (from data set 1) was discarded owing to image artifacts leading to inaccurate surfaces.

For each subject, thickness measures across the cortex were computed by finding the point on the gray-white boundary surface that was closest to a given point on the estimated pial surface (and vice versa) and averaging between these 2 values.<sup>17</sup> The accuracy of the thickness measures derived from this technique have been validated by direct comparisons with manual measures on postmortem brains.<sup>30</sup>

### Inflation, Registration, and Intersubject Averaging

The surface representing the gray-white border was inflated,<sup>18,20</sup> differences between individuals in the depth of gyri/sulci were normalized, and each subject's reconstructed brain was then morphed and registered to an average spherical surface representation that optimally aligned sulcal and gyral features across subjects.<sup>20,31</sup> This spherical morphing procedure was used to compute the average thickness within ROIs and to construct the cortical thickness difference brain maps.

### Computation of Average Cortical Thickness Within ROIs

We selected the following 4 anatomical regions in the frontal lobe and 2 anatomical regions in the temporal lobe that we hypothesized would show group differences: the inferior frontal gyrus, the dorsolateral prefrontal cortex (broadly defined as the middle frontal gyrus plus superior frontal sulcus), the anterior cingulate gyrus, the orbitofrontal cortex (defined as the fronto-orbital gyrus plus orbital sulci), the parahippocampal gyrus, and the superior temporal gyrus. In addition, we se-

lected the following 6 control ROIs that we predicted would not show significant difference in cortical thickness between groups: the central sulcus, the precentral gyrus, the postcentral gyrus, the postcentral sulcus and intraparietal lobule, the superior parietal lobule, and the calcarine fissure. These ROIs were drawn on maps of average folding patterns (derived using the surface-based morphing procedure as described by Fischl et al<sup>20,31</sup>) on the cortical surface of each hemisphere, with reference to an anatomical atlas<sup>32</sup> (**Figure 1**).

Each ROI was mapped back on to each individual subject's unfolded surface by applying the same algorithm that morphed each subject's unfolded surface to the average spherical surface representation<sup>20,31</sup> in reverse (**Figure 2**).

The average thickness within each ROI in each hemisphere in each individual subject was the dependent variable in a repeated-measures analysis of variance, with subjects as a random effect and group as a between-subject factor (2 levels: patients and controls). Region type (2 levels: temporal-prefrontal and control regions) and hemisphere (2 levels: right and left) were within-subject factors. Data set was entered into the model as a potentially confounding covariate. Analyses were repeated with the average thickness of each individual over the entire cortical surface as an additional covariate. We used a standard level of  $\alpha = .05$  to determine whether effects reached significance.

### Computation of Mean and Statistical Cortical Thickness Difference Maps

We used the spherical transformation to map the thickness measurements at each vertex on each subject's cortical surface into a common spherical coordinate system.<sup>20,31</sup> The data were smoothed on the surface tessellation using an iterative nearest-neighbor averaging procedure (1000 iterations were applied, equivalent to applying a 2-dimensional gaussian smoothing kernel along the cortical surface with a full-width half-maximum of approximately 6 cm). Data were then averaged across participants in the spherical coordinate system<sup>31</sup> to generate mean maps showing the mean differences in thickness (in millimeters) between the patient and control groups at multiple uniformly sampled loci across the cortical surface (**Figure 3D**).

Statistical thickness difference maps were constructed using a *t* statistic (Figure 3A-C). We used a general linear model in which the main effects of group (thickness differences between patients and controls) are shown, covarying for age, sex, and years of education. For the map in which data sets 1 and 2 were combined (Figure 3C), data set was an additional covariate. We had strong a priori hypotheses that differences would be observed within the prefrontal and temporal cortices. Given their surface area and the degree of surface smoothing applied, 42 effective tests were conducted within these temporal-prefrontal regions. Applying a Bonferroni correction, an uncorrected threshold of  $P < .001$  is approximately equivalent to a corrected threshold of  $P < .05$  (ie, 5% expected false-positive findings). The regions displayed in yellow on the brainmaps all met this criterion for significance. We also display thickness differences at subthreshold levels (an uncorrected threshold of  $P < .05$ ) in red. This was to examine the full extent of cortical thickness differences across the cortical surface, particularly in data sets 1 and 2 that were collected independently on different scanners, and to determine whether regions outside temporal-prefrontal regions showed any hint of thinning in patients with schizophrenia.

### Manual Validation

Automated estimates of thickness in 2 regions that did and did not show significant ( $P < .001$ ) between-group differences on

the statistical thickness difference maps were validated to be reliable to less than 0.5 mm by direct comparisons with manual measures made on slice MR data (**Figure 4**).

## RESULTS

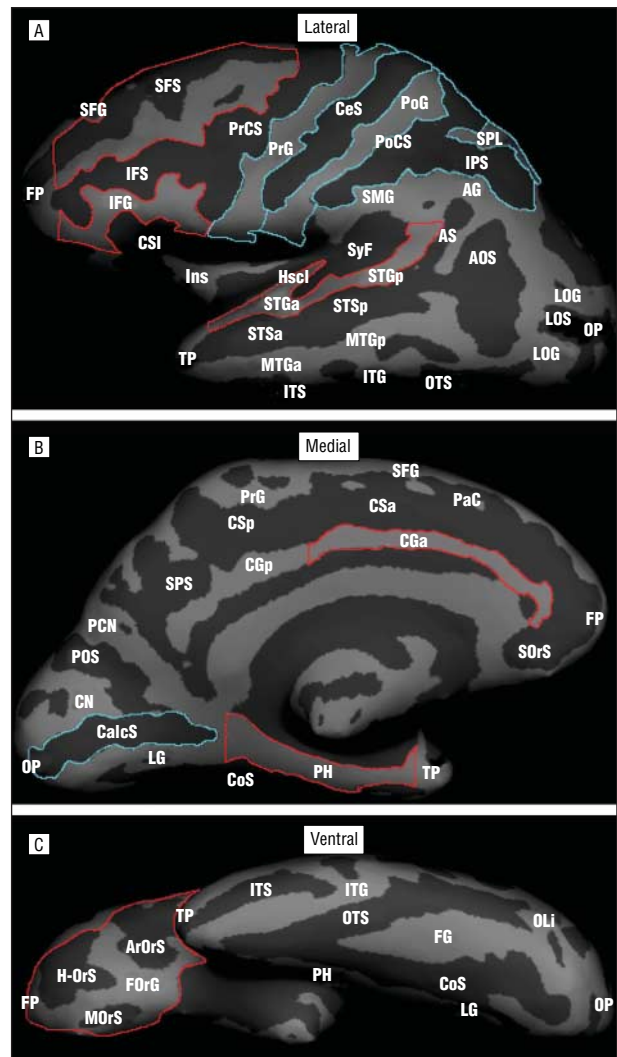
### REGIONS OF INTEREST

**Table 2** presents the mean and percentage differences in cortical thickness between patients and controls in all of these ROIs (averaged across the right and left hemispheres). An analysis of variance showed a significant interaction between group (patients vs controls) and region type (temporal-prefrontal regions vs control ROIs) ( $F_{1,61}=7.23$ ;  $P<.009$ ). This interaction remained significant when we covaried for the average thickness across the entire cortex in each individual ( $F_{1,61}=5.25$ ;  $P<.02$ ). Follow-up analyses confirmed that patients showed significant thinning (relative to controls) in the temporal-prefrontal cortices ( $F_{1,61}=4.6$ ;  $P<.03$ ), but not in control regions ( $F_{1,61}=2.5$ ;  $P=.12$ ). There were no significant interactions between data set and group.

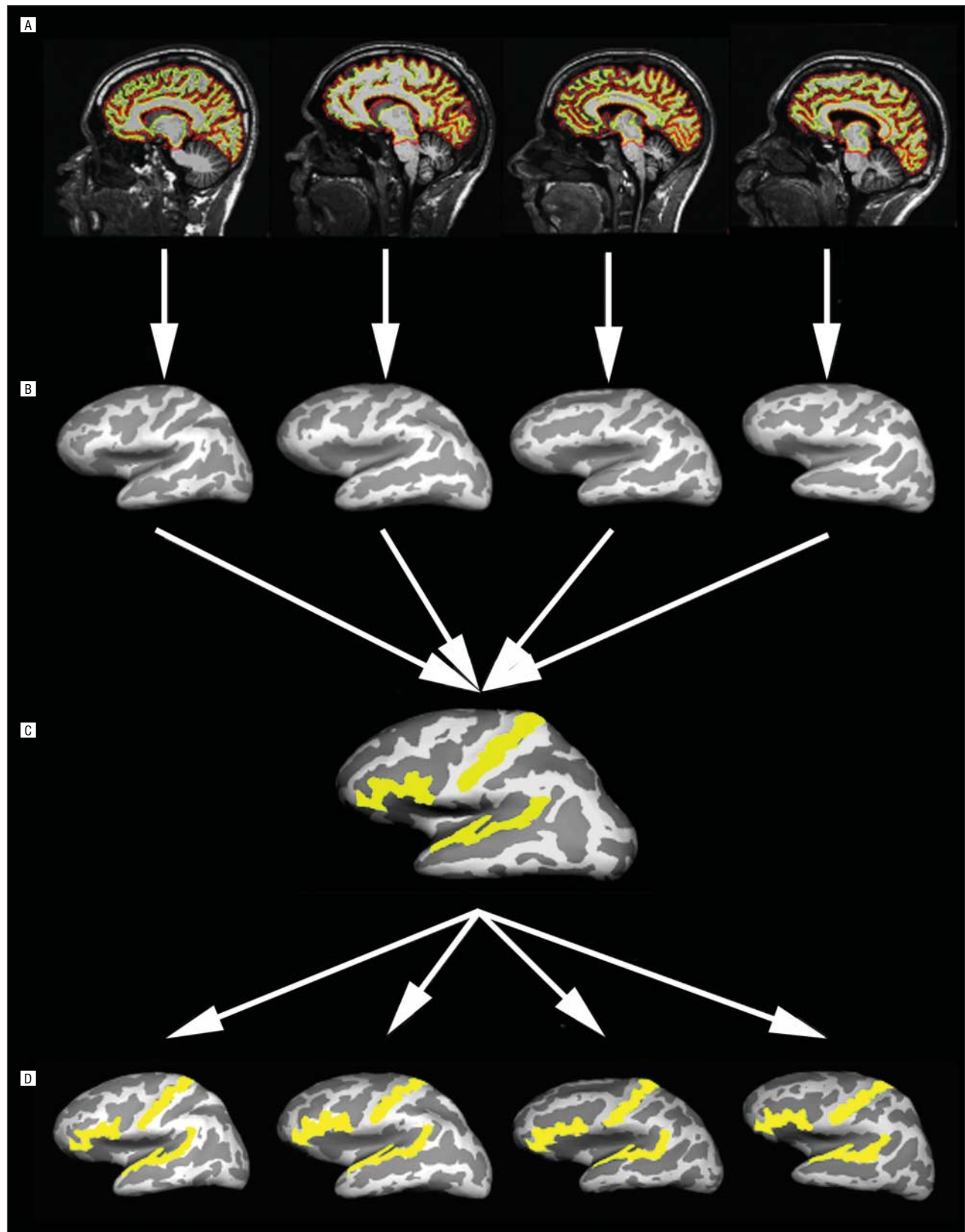
### CORTICAL THICKNESS DIFFERENCE MAPS

Figure 3 (rows A and B) shows statistical difference maps of data sets 1 and 2 at an uncorrected threshold of  $P<.05$ . The overall pattern of thinning across the cortical surface was strikingly similar in both data sets, although they constituted independently recruited patients and controls who underwent scanning on different systems. This provided some internal validation of our main finding. Thinning was most apparent in the prefrontal cortex (particularly in the inferior frontal, orbitofrontal, and medial prefrontal cortices) and in the temporal cortex (superior, middle, and inferior temporal cortices, fusiform and parahippocampal gyri, and temporal poles). Thinning was also observed in the left occipitotemporal junction and the left insula. In both data sets, the primary visual cortex, central sulcus, precentral and postcentral gyri, and superior parietal cortex appeared to be relatively (although not entirely) spared. In data set 1, a small region of relative thickening was found in the patients around the central sulcus that is probably an artifact arising from suboptimal gray-white contrast in this region. Artifacts of thickening were not observed in data set 2, where the acquisition sequence yielded better gray-white contrast in this region.

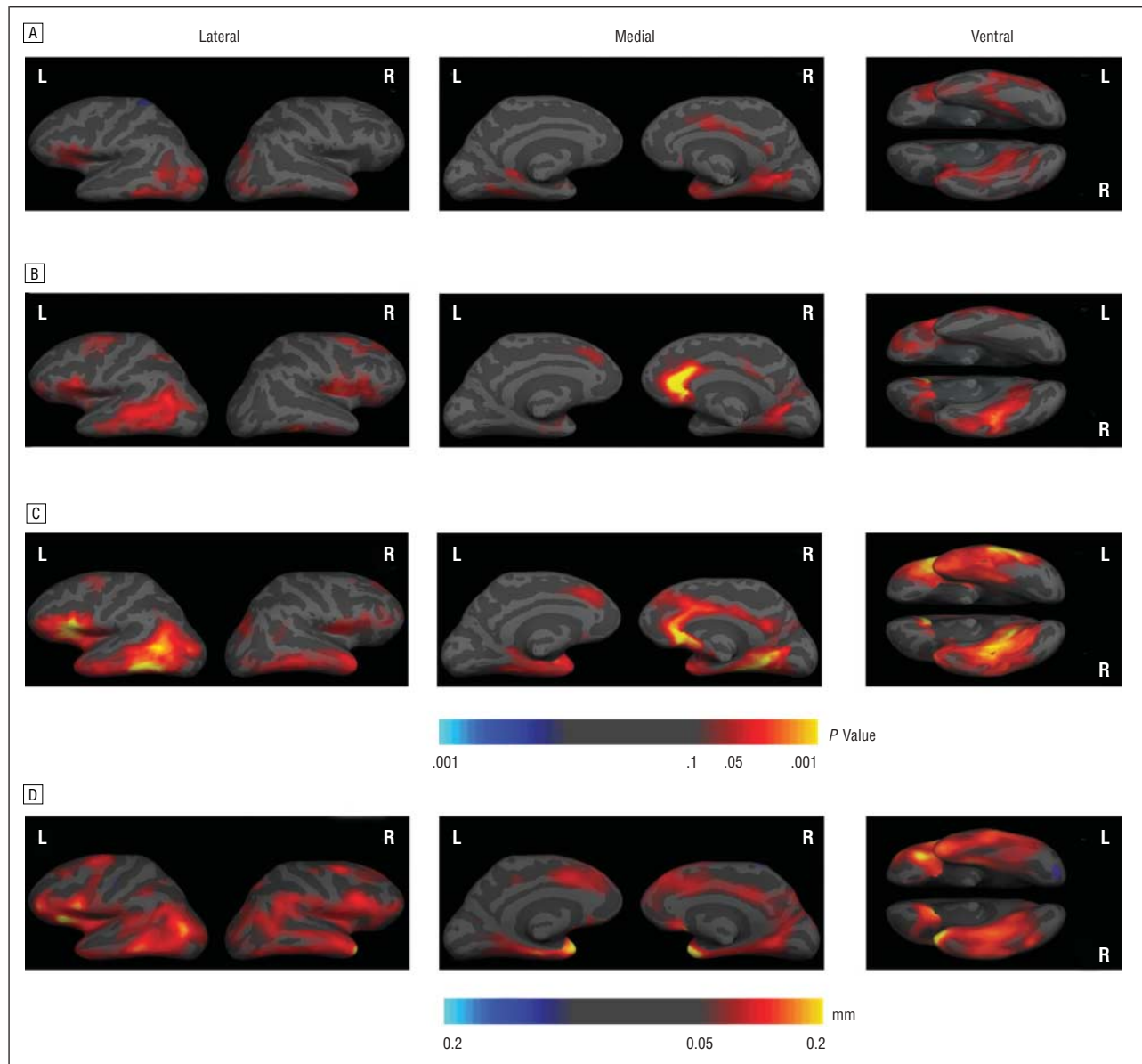
To maximize statistical power and to determine patterns of cortical thinning that were most robust across all patients and controls, we combined the 2 data sets to construct an overall statistical thickness difference map, covarying for the effect of data set (Figure 3C). Identical numbers of patients and controls were included in each data set, making it unlikely that their combination would systematically confound findings. This was confirmed by an analysis of variance that showed a significant main effect of group in global cortical thickness (ie, thickness across the entire cortical surface, collapsing across both hemispheres and data sets) (patients, 2.26 mm; controls, 2.32 mm;  $F_{1,60}=5.30$ ;  $P=.03$ ), but no scanner  $\times$  group interaction ( $F_{1,60}=0.005$ ;  $P=.95$ ).



**Figure 1.** Lateral, medial, and ventral surfaces of the left hemisphere with average folding patterns of sulci (dark gray) and gyri (light gray), derived using the surface-based morphing procedure.<sup>20,31</sup> Temporal-prefrontal regions of interest (ROIs) are shown in red. Lateral surface (A) includes dorsolateral prefrontal cortex (middle frontal gyrus and superior frontal sulcus), inferior frontal gyrus, and superior temporal gyrus. Medial surface (B) includes parahippocampal gyrus and anterior cingulate gyrus. Ventral surface (C) includes orbitofrontal cortex (H-shaped orbital sulcus, arcuate orbital sulcus, medial orbital sulcus, and fronto-orbital gyrus). Control ROIs are shown in blue. Lateral surface (A) includes central sulcus, precentral and postcentral gyri, the intraparietal sulcus, postcentral sulcus, and the superior parietal lobule. Medial surface (B) includes the calcarine fissure. Lowercase a indicates anterior; AG, angular gyrus; AOS, anterior occipital sulcus; ArOrS, arcuate orbital sulcus; AS, angular sulcus; CalcS, calcarine sulcus; CeS, central sulcus; CGa, anterior cingulate sulcus; CGp, posterior cingulate gyrus; CN, cuneus; CoS, collateral sulcus; CSa, anterior cingulate sulcus; CSI, circular sulcus of insula; CSp, posterior cingulate sulcus; FG, fusiform gyrus; FOrG, fronto-orbital gyrus; FP, frontal pole; H-OrS, H-shaped orbital sulcus; Hscl, Heschl's gyrus; IFG, inferior frontal gyrus; IFS, inferior frontal sulcus; Ins, insula; IPS, intraparietal sulcus; lower case p, posterior; PaC, paracingulate cortex; PCN, precuneus; PH, parahippocampal gyrus; PoCS, postcentral sulcus; PoG, postcentral gyrus; POS, parieto-occipital sulcus; PrCS, precentral sulcus; PrG, precentral gyrus; SFG, superior frontal gyrus; SFS, superior frontal sulcus; SMG, supramarginal gyrus; SOrS, superior orbital sulcus; SPL, superior parietal lobule; SPS, subparietal sulcus; STG, superior temporal gyrus; STS, superior temporal sulcus; SyF, sylvian fissure; and TP, temporal pole.



**Figure 2.** Cortical reconstruction procedures. A, Sagittal sections through individual brains (2 control subjects, left; 2 patients, right) with representations of the gray matter–white matter boundary (yellow line) and the pial surface (red line). B, Inflated cortical surfaces showing sulcal-gyral folding patterns of the same 4 individual brains. C, Each subject's reconstructed brain was morphed to a template guided by the mean and variance of the folding pattern at each point in the cortex,<sup>20,31</sup> and regions of interest (ROIs) were painted onto this common surface template (the left inferior frontal gyrus, left superior temporal gyrus, and left central sulcus are illustrated in yellow). D, The transformation was reversed such that the ROIs were mapped back onto the cortical surfaces of each individual participant.

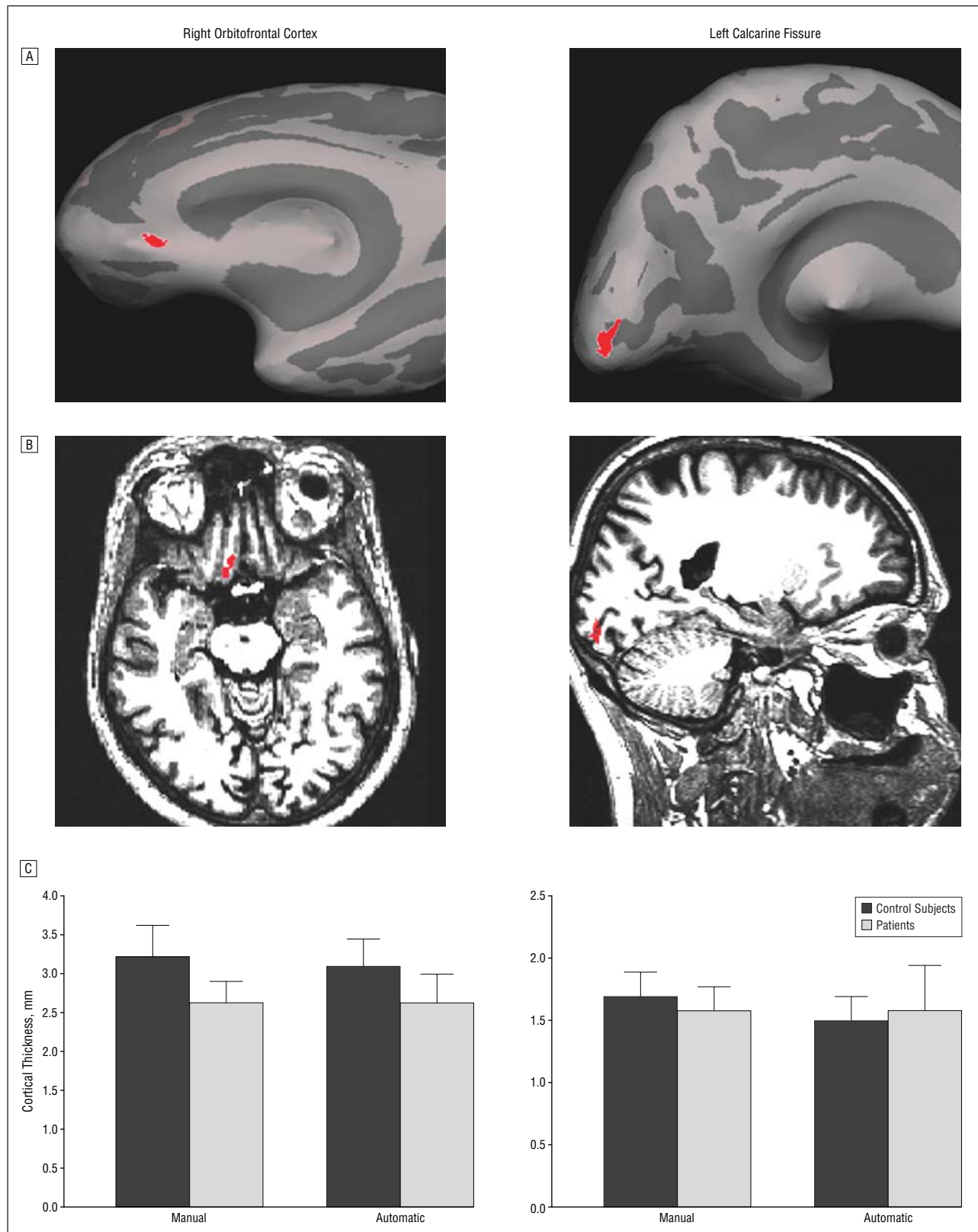


**Figure 3.** Statistical thickness difference maps from data sets 1 (A) and 2 (B) and the combined data sets (C). In mean thickness difference maps (D), yellow corresponds to mean thickness difference of at least 0.2 mm (percentage reduction in thickness of at least 8.7%). Cortical thickness differences are displayed on the average curvature (see Figure 1), with sulcal and gyral folds shown in light and dark gray, respectively. R indicates right; L, left.

Moreover, there were no significant interactions between group and data set in the ROI analyses described herein.

As shown in Figure 3C, regions of statistically thinner cortex in patients relative to controls (at  $P < .001$  uncorrected; equivalent to  $P < .05$  corrected, shown in yellow) included the orbitofrontal cortices bilaterally (approximate Brodmann areas [BAs] 10 and 11), the left inferior frontal gyrus (approximate BAs 44 and 45), the right medial frontal cortex (approximate BAs 32 and 24), the left occipitotemporal junction (approximate BAs 22, 21, and 37), the right medial temporal cortex (approximate BAs 28, 27, 34, and 35), and the left inferior temporal gyrus (approximate BA 20). All these regions except for the right orbitofrontal and right medial frontal cortices showed significant differences when the average thickness across the entire cortex in each individual was included as an additional covariate. At a subthresh-

old significance level ( $P < .05$ , uncorrected, shown in red) thinning in the patients was also observed in the right inferior frontal cortex (BAs 44, 45, and 47), the dorso-lateral prefrontal cortex bilaterally (approximate BAs 8, 9, and 46), the left anterior medial frontal cortex (approximate BAs 32 and 24), the right inferior temporal cortex (approximate BA 20), the left medial temporal lobe (approximate BAs 27, 28, 34, and 35), the temporal poles bilaterally (approximate BAs 20 and 38), the fusiform gyri bilaterally (BA 37), and the left insula. These regions did not show significant differences in thickness when we covaried for the average thickness across the entire cortex in each individual. Even at  $P < .05$  uncorrected, the superior parietal cortex and primary visual, somatosensory, and motor cortices appeared to be relatively spared. Moreover, although our tests were 2-tailed, the amount of thinning was overwhelmingly greater than thickening



**Figure 4.** Manual validation of automated thickness measures. A, Two small regions shown in red within the right orbitofrontal cortex (left panel) and the left calcarine sulcus (right panel) that did and did not show significant between-group differences, respectively, on the statistical thickness difference maps (Figure 3). B, These 2 regions were each mapped back onto the corresponding brain volumes of each of the 32 individual subjects in data set 2 using the spherical morphing algorithm applied in reverse (1 patient's brain volume is shown). Manual thickness measures of these 2 regions in each individual's volume were estimated by taking the shortest distance (over 3 cross-sectional views) between a visual estimate of the gray-white border and the pial surface, averaged across 10 points within each region. C, Mean and SDs of manual estimates of thickness were similar to the automated estimates of thickness in both patient and control groups. There was a significant difference between patients and control subjects in manual estimates of thickness in the right orbitofrontal cortex ( $t=4.63$ ;  $P<.0001$ ) but not in the left calcarine fissure ( $t=1.50$ ;  $P=.14$ ).

in the patients compared with the controls, ie, even at  $P < .05$  uncorrected, virtually no false-positive findings were detected for thickening.

Figure 3D shows a map with mean differences in cortical thickness at uniformly sampled loci across the entire cortex, confirming an overall pattern of temporal-prefrontal thinning in the patients relative to controls.

### EFFECTS OF DEMOGRAPHIC AND PSYCHOPATHOLOGICAL VARIABLES ON CORTICAL THICKNESS

In the patient group, age was significantly inversely correlated with cortical thickness (ie, thinner cortex with older age) in all temporal-prefrontal ROIs (all Pearson correlations,  $P < .004$ ) except for the parahippocampal gyri ( $P = .68$ ). In the control group, age showed significant inverse correlations with cortical thickness in all temporal-prefrontal ROIs ( $P < .04$ ) except in the anterior cingulate cortices ( $P = .51$ ) and the parahippocampal gyri ( $P = .58$ ). There were no significant age  $\times$  group interactions in any of the ROIs, ie, there was no evidence of different age-related effects between the 2 groups ( $P > .05$  for all).

Years of education did not correlate with cortical thickness in any of the temporal-prefrontal ROIs in the patient or the control group. There were no significant differences in cortical thickness between men and women within the patient or the control group ( $P > .20$  for all). Within the patient group, there were no significant correlations between cortical thickness in any of the temporal-prefrontal ROIs and medication dosage as indexed by chlorpromazine equivalents ( $P > .83$  for all) or severity of illness as assessed using the global Positive and Negative Syndrome Scale (PANSS) score ( $P > .21$  for all). There were significant correlations between cortical thickness and duration of illness in the inferior frontal cortex ( $P < .05$ ), the dorsolateral prefrontal cortex ( $P < .02$ ), and the anterior cingulate gyrus ( $P < .01$ ). These correlations, however, did not remain significant when age was covaried as a potentially confounding variable ( $P > .35$  for all).

### QUANTITATIVE RELATIONSHIPS BETWEEN ROI AND BRAINMAP THICKNESS MEASURES

We mapped the more focal regions that showed significant ( $P < .001$ ) differences in the combined statistical thickness difference map (Figure 3C) back on each individual subject's cortical surface and calculated the average thickness within each of these focal regions in each individual. Within both groups, focal thickness within the left inferior frontal gyrus correlated significantly ( $P < .05$ ) with the overall average thickness across all temporal-prefrontal ROIs. In the control group, but not the patient group, the other focal regions that correlated significantly with overall temporal-prefrontal thickness were the left occipitotemporal junction ( $P < .03$ ), the left inferior temporal cortex ( $P < .03$ ), and the right medial temporal cortex ( $P < .01$ ).

When we covaried for overall temporal-prefrontal thickness in each individual, there remained significant

**Table 2. Mean Cortical Thickness in Patient and Control Groups in Selected Regions of Interest**

Region	Mean (SE) Thickness, mm		Difference, %
	Schizophrenic Patients	Control Subjects	
Temporal-frontal regions of interest			
Inferior frontal gyrus	2.50 (0.037)	2.64 (0.035)	5.30
Dorsolateral prefrontal cortex	2.29 (0.029)	2.36 (0.031)	2.97
Anterior cingulate gyrus	2.71 (0.052)	2.83 (0.048)	4.24
Orbitofrontal cortex	2.50 (0.038)	2.57 (0.034)	2.72
Superior temporal gyrus	2.65 (0.039)	2.71 (0.034)	2.21
Parahippocampal gyrus	2.73 (0.039)	2.83 (0.031)	3.53
Control regions of interest			
Central sulcus	1.60 (0.041)	1.59 (0.049)	-0.63
Precentral gyrus	2.40 (0.030)	2.32 (0.032)	-3.45
Postcentral gyrus	2.07 (0.023)	2.02 (0.019)	-2.48
Postcentral sulcus and intraparietal sulcus	1.93 (0.014)	1.86 (0.022)	-3.76
Superior parietal lobule	2.18 (0.022)	2.20 (0.019)	-0.91
Calcarine fissure	1.59 (0.089)	1.49 (0.048)	-6.71

( $P < .01$ ) differences between patients and controls in the thickness of all focal regions.

### COMMENT

#### SUMMARY OF MAIN FINDINGS

Using MR methods, we have demonstrated, for the first time to our knowledge, regionally selective thinning of the cortical ribbon in schizophrenia. The ROI analysis showed that cortical thinning was significantly greater in patients with schizophrenia (relative to matched controls) in temporal-prefrontal ROIs than in selected control ROIs (the superior parietal cortex and primary visual, somatosensory, and motor cortices). This was the case even when we covaried for global thickness across the entire cortex in each individual subject.

Both the mean thickness difference maps and sub-threshold statistical thickness difference maps (for data sets 1 and 2 individually) confirmed an overall distribution of cortical thinning that primarily affected prefrontal and temporal cortices while relatively sparing the superior parietal cortex, primary visual regions, the central sulcus, or the precentral and postcentral gyri. The statistical thickness difference map that combined both data sets showed significant thinning within several more focal regions within the left lateral and inferior temporal-prefrontal cortex (left inferior frontal, orbitofrontal, inferior temporal, and occipitotemporal cortices) and within the right medial temporal-prefrontal cortex (right medial temporal, orbitofrontal, and medial frontal cortices). In comparing the ROI and brainmap findings more quantitatively, cortical thinning averaged across all temporal-prefrontal ROIs in patients relative to controls did not entirely explain thinning in these more focal regions, sug-



gesting that thinning was nonhomogeneous within the temporal-prefrontal cortex.

### POTENTIAL CONFOUNDS

We attempted to exclude several methodological factors as potential confounds of our main finding that cortical thinning in patients (relative to controls) was greater in temporal-prefrontal than control regions. First, we visually inspected the entire cortex in each individual subject, slice by slice, manually fixing any inaccuracies in segmentation that might have arisen from image artifact. Second, to exclude the possibility that our main finding arose as a result of systematic differences in the registration of the main cortical folds in the schizophrenic and control groups, we checked the accuracy of registration of the major gyri/sulci binding ROIs in each patient and control participant (Figure 2). Third, to exclude the possibility that our main finding was driven by differences between temporal-prefrontal and control regions in the between-subject variability of cortical thickness, we constructed mean thickness difference maps (that do not take into account variance between subjects). The overall pattern of thinning in these mean thickness difference maps (Figure 3D) was qualitatively similar to that seen in the statistical thickness maps (Figure 3C).

### COMPARISON WITH PREVIOUS STUDIES OF VOLUMETRIC CHANGES IN SCHIZOPHRENIA

Volume is a product of cortical thickness and surface area. Volumetric deficits have been previously described in all of the regions in which we report cortical thinning in the present study,<sup>1,2,8-10</sup> suggesting that cortical thinning may contribute to volumetric abnormalities in schizophrenia. Reduced surface area has also been reported in some of the regions in which we demonstrated cortical thinning, such as the orbitofrontal cortex.<sup>33</sup> Surface area and thickness are known to result from distinct stages during cortical development.<sup>34</sup> If, as hypothesized, schizophrenia arises from abnormal neurodevelopment,<sup>35-37</sup> understanding the relationships between volume, thickness, and surface area will shed further light on its pathogenesis.

Because the methods we used probed gray matter thickness rather than volume, they do not index gray matter deficits that have been previously documented in subcortical structures such as the hippocampus<sup>38</sup> and the thalamus.<sup>39</sup> However, both of these subcortical regions have dense reciprocal projections with the cortical regions in which we observed thinning. Our findings are therefore consistent with models that have emphasized the role of hippocampocortical and thalamocortical circuitry in the pathoetiology of schizophrenia.<sup>38-40</sup>

### RELATIONSHIP WITH ABNORMALITIES REVEALED BY NEUROPATHOLOGICAL STUDIES

Abnormalities in cortical thickness in temporal and prefrontal regions may reflect underlying histopathological changes in these regions. Indeed, a recent study that used magnetization transfer imaging techniques suggested

subtle or early neuropathological abnormalities in many of these temporal-prefrontal regions in patients with schizophrenia.<sup>41</sup> What specific neuropathological abnormalities might underlie the cortical thinning we observed in the current study? Although there is evidence of volume loss and a decrease in the total number of cells in the hippocampus and thalamus, the precise nature of neuropathological abnormalities in the cerebral cortex in schizophrenia remains more controversial.<sup>14-16</sup> Almost all postmortem studies report only changes in cell density and do not report a reference volume, making it difficult to determine whether there is a loss in the total number of cells in the cortex.<sup>14</sup> Some studies have reported cell-specific or layer-specific decreases in nerve cell density, particularly in interneurons in the prefrontal cortex.<sup>42</sup> Others, however, report increases in cell density<sup>43,44</sup> and, by inference, a decrease in the amount of interneuronal neuropil, in regions such as the dorsolateral prefrontal cortex.<sup>45</sup> The precise relationships between these findings and overall cortical thickness remain undetermined. Combining the techniques presented herein with postmortem analysis, by targeting regions with maximal cortical thinning, may help clarify the neuropathological basis of morphological changes in schizophrenia.

### RELATIONSHIP WITH FUNCTIONAL AND COGNITIVE ABNORMALITIES IN SCHIZOPHRENIA

The pattern of gray matter cortical deficits described in the present study can be linked with neuropsychological deficits in schizophrenia in a variety of cognitive domains.<sup>11</sup> Temporal and inferior frontal atrophy may lead to abnormalities in semantic and language function; gray matter deficits in the dorsolateral prefrontal cortex may be linked with working memory and executive dysfunction; medial temporal lobe deficits may contribute to declarative memory dysfunction; and atrophy in the orbitofrontal, cingulate, and insula cortices may underlie abnormalities in emotional and social cognition.<sup>11</sup> Abnormal patterns of activation in all of the regions that showed cortical thinning in this study have been described in functional neuroimaging studies in schizophrenia during cognitive activation paradigms of language and semantic processing,<sup>46</sup> declarative memory,<sup>47</sup> working memory,<sup>48,49</sup> emotional processing,<sup>50</sup> and social cognition.<sup>51</sup> We are currently using the same cortical reconstruction and surface-based averaging techniques described herein in our analysis of functional MRI data. This will help discriminate between an anatomical vs a functional basis of activation abnormalities in schizophrenia, and allow us to address the fundamental question of how brain structure and function are linked in schizophrenia.

### CONCLUSIONS

We have demonstrated selective thinning of the cerebral cortex within the temporal and prefrontal cortices in patients with schizophrenia. There are important considerations in the interpretation of our data. First, al-

though we showed no significant correlations between cortical thickness in ROIs and overall disease severity as indexed using the global PANSS score, schizophrenia is a clinically heterogeneous disorder and the PANSS includes a wide variety of positive and negative symptoms. The findings reported herein could very well have arisen as expressions of effects in only parts of the clinical group. Evidence from volumetric studies suggests that some psychopathological variables, such as positive thought disorder,<sup>52</sup> auditory hallucinations,<sup>53</sup> negative symptoms,<sup>9</sup> and global function,<sup>54</sup> are correlated with morphometric changes in particular regions. We hope to determine whether these variables are also correlated with regional differences in cortical thinning in future studies in larger samples with a wider range of clinical symptoms and disease severity. It will also be interesting to determine whether regional cortical thinning is more marked in patients with a positive family history of schizophrenia.<sup>55</sup>

Second, both of the samples described herein included patients receiving long-term medication therapy. Volumetric reductions in some of the same regions in which we report thinning have been described in schizophrenic patients in their first episode of illness.<sup>56</sup> Future studies using this technique will determine whether first-episode schizophrenic patients also show cortical thinning. In the present study, medication dosage and illness duration (covarying for age) did not predict cortical thinning in ROIs. However, we do not wish to overinterpret these nonsignificant correlations. Previous studies have suggested that patients may show a greater rate of decline with age in gray matter volume than controls.<sup>57,58</sup> Future studies in a larger sample of patients will determine whether this is also true of cortical thickness changes. Indeed, the methods presented herein have potential for longitudinal studies of cortical thickness in schizophrenia. They are automated and objective and can be used to detect subtle changes in thickness over time, even in individual subjects. This will allow us to determine changes during the course of the schizophrenic illness and the effects of different pharmacological treatments.

Submitted for publication November 1, 2002; final revision received January 27, 2003; accepted January 30, 2003.

Dr Kuperberg was supported by the Wellcome Trust, London, England, and is currently supported by grant K23 PA-00-004 from the National Institute of Mental Health, Rockville, Md. This work was also supported by the Institute for Mental Illness and Neuroscience Discovery, Albuquerque, NM. Dr Ozawa was supported by Hamamatsu Photonics, Shizuoka, Japan.

This research used a computer program, FreeSurfer, for data analysis. FreeSurfer, distributed freely for research purposes, is co-owned by an entity in which Dr Dale has a financial interest.

We thank Stephan Heckers, MD, for helpful discussion on the neuropathology of schizophrenia in relation to the current findings and Bruce Rosen, MD, PhD, for helpful discussion.

Corresponding author and reprints: Gina R. Kuperberg, MD, PhD, MRCPsych, Department of Psychiatry, Massachu-

setts General Hospital (East), CNY-9, Bldg 149, Charlestown, MA 02129 (e-mail: kuperber@nmr.mgh.harvard.edu).

## REFERENCES

- Shenton ME, Dickey CC, Frumin M, McCarley RW. A review of MRI findings in schizophrenia. *Schizophr Res*. 2001;49:1-52.
- Goldstein JM, Goodman JM, Seidman LJ, Kennedy DN, Makris N, Lee H, Tourville J, Caviness VS Jr, Faraone SV, Tsuang MT. Cortical abnormalities in schizophrenia identified by structural magnetic resonance imaging. *Arch Gen Psychiatry*. 1999;56:537-547.
- Wright IC, McGuire PK, Poline JB, Traverso JM, Murray RM, Frith CD, Frackowiak RS, Friston KJ. A voxel-based method for the statistical analysis of gray and white matter density applied to schizophrenia. *Neuroimage*. 1995;2:244-252.
- Ashburner J, Friston KJ. Voxel-based morphometry: the methods. *Neuroimage*. 2000;11(pt 1):805-821.
- Thompson PM, Vidal C, Giedd JN, Gochman P, Blumenthal J, Nicolson R, Toga AW, Rapoport JL. Mapping adolescent brain change reveals dynamic wave of accelerated gray matter loss in very early-onset schizophrenia. *Proc Natl Acad Sci U S A*. 2001;98:11650-11655.
- Cannon TD, Thompson PM, van Erp TG, Toga AW, Poutanen VP, Huttunen M, Lonnqvist J, Standerskjold-Nordenstam CG, Narr KL, Khaledy M, Zoumalan CI, Dail R, Kaprio J. Cortex mapping reveals regionally specific patterns of genetic and disease-specific gray-matter deficits in twins discordant for schizophrenia. *Proc Natl Acad Sci U S A*. 2002;99:3228-3233.
- Talairach J, Tournoux P. *Co-Planar Stereotaxic Atlas of the Human Brain*. New York, NY: Thieme Medical Publishers Inc; 1988.
- Wright IC, Ellison ZR, Sharma T, Friston KJ, Murray RM, McGuire PK. Mapping of grey matter changes in schizophrenia. *Schizophr Res*. 1999;35:1-14.
- Sigmundsson T, Suckling J, Maier M, Williams S, Bullmore E, Greenwood K, Fukuda R, Ron M, Toone B. Structural abnormalities in frontal, temporal, and limbic regions and interconnecting white matter tracts in schizophrenic patients with prominent negative symptoms. *Am J Psychiatry*. 2001;158:234-243.
- Hulshoff Pol HE, Schnack HG, Mandl RC, van Haren NE, Koning H, Collins DL, Evans AC, Kahn RS. Focal gray matter density changes in schizophrenia. *Arch Gen Psychiatry*. 2001;58:1118-1125.
- Kuperberg G, Heckers S. Schizophrenia and cognitive function. *Curr Opin Neurol*. 2000;10:205-210.
- Zilles K. *Cortex*. The Human Nervous System. Orlando, Fla: Academic Press Inc; 1990:575-802.
- von Economo C. *The Cytoarchitectonics of the Human Cerebral Cortex*. New York, NY: Oxford University Press Inc; 1929.
- Heckers S. Neuropathology of schizophrenia: cortex, thalamus, basal ganglia, and neurotransmitter-specific projection systems. *Schizophr Bull*. 1997;23:403-421.
- Selemon LD. Regionally diverse cortical pathology in schizophrenia: clues to the etiology of the disease. *Schizophr Bull*. 2001;27:349-377.
- Harrison PJ. The neuropathology of schizophrenia: a critical review of the data and their interpretation. *Brain*. 1999;122(pt 4):593-624.
- Fischl B, Dale AM. Measuring the thickness of the human cerebral cortex from magnetic resonance images. *Proc Natl Acad Sci U S A*. 2000;97:11050-11055.
- Dale AM, Sereno MI. Improved localization of cortical activity by combining EEG and MEG with MRI cortical surface reconstruction: a linear approach. *J Cogn Neurosci*. 1993;5:162-176.
- Dale AM, Fischl B, Sereno MI. Cortical surface-based analysis. I: segmentation and surface reconstruction. *Neuroimage*. 1999;9:179-194.
- Fischl B, Sereno MI, Dale AM. Cortical surface-based analysis. II: inflation, flattening, and a surface-based coordinate system. *Neuroimage*. 1999;9:195-207.
- Fischl B, Liu A, Dale AM. Automated manifold surgery: constructing geometrically accurate and topologically correct models of the human cerebral cortex. *IEEE Trans Med Imaging*. 2001;20:70-80.
- Oldfield RC. The assessment and analysis of handedness: the Edinburgh Inventory. *Neuropsychologia*. 1971;9:97-113.
- White K, Ashton R. Handedness assessment inventory. *Neuropsychologia*. 1976;14:261-264.
- Spitzer RL, Williams JB, Gibbon M, First MB. The Structured Clinical Interview for DSM-III-R (SCID). I: history, rationale, and description. *Arch Gen Psychiatry*. 1992;49:624-629.
- American Psychiatric Association. *Diagnostic and Statistical Manual of Mental Disorders, Fourth Edition*. Washington, DC: American Psychiatric Association; 1994.
- Nelson HE. *The National Adult Reading Test (NART)*. Windsor, Ontario: NFER-Nelson; 1982.
- Blair JR, Spreen O. Predicting premorbid IQ: a revision of the National Adult Reading Test. *Clin Neuropsychol*. 1989;3:129-136.

28. Hollingshead AB. *Two Factor Index of Social Position*. New Haven, Conn: Yale University Press; 1965.
29. Kay SR, Fiszbein A, Opler LA. The positive and negative syndrome scale (PANSS) for schizophrenia. *Schizophr Bull*. 1987;13:261-276.
30. Rosas HD, Liu AK, Hersch S, Glessner M, Ferrante RJ, Salat DH, van der Kouwe A, Jenkins BG, Dale AM, Fischl B. Regional and progressive thinning of the cortical ribbon in Huntington's disease. *Neurology*. 2002;58:695-701.
31. Fischl B, Sereno MI, Tootell RB, Dale AM. High-resolution intersubject averaging and a coordinate system for the cortical surface. *Hum Brain Mapp*. 1999;8:272-284.
32. Duvernoy HM, Bourgouin Maeder P, Cabanis EA, Cattin F, Guyot J, Iba-Zizen MT. *The Human Brain: Surface Three-Dimensional Sectional Anatomy and MRI*. 2nd ed. New York: Springer-Verlag NY Inc; 2001.
33. Crespo-Facorro B, Kim J, Andreasen NC, O'Leary DS, Magnotta V. Regional frontal abnormalities in schizophrenia: a quantitative gray matter volume and cortical surface size study. *Biol Psychiatry*. 2000;48:110-119.
34. Rakic P. Specification of cerebral cortical areas. *Science*. 1988;241:170-176.
35. Feinberg I. Schizophrenia: caused by a fault in programmed synaptic elimination during adolescence? *J Psychiatr Res*. 1982;17:319-334.
36. Murray RM. Neurodevelopmental schizophrenia: the rediscovery of dementia praecox. *Br J Psychiatry Suppl*. November 1994;25:6-12.
37. Weinberger DR. From neuropathology to neurodevelopment. *Lancet*. 1995;346:552-557.
38. Nelson MD, Saykin AJ, Flashman LA, Riordan HJ. Hippocampal volume reduction in schizophrenia as assessed by magnetic resonance imaging: a meta-analytic study. *Arch Gen Psychiatry*. 1998;55:433-440.
39. Konick LC, Friedman L. Meta-analysis of thalamic size in schizophrenia. *Biol Psychiatry*. 2001;49:28-38.
40. Hulshoff Pol HE, Schnack HG, Bertens MG, van Haren NE, van der Tweel I, Staal WG, Baare WF, Kahn RS. Volume changes in gray matter in patients with schizophrenia. *Am J Psychiatry*. 2002;159:244-250.
41. Foong J, Symms MR, Barker GJ, Maier M, Woermann FG, Miller DH, Ron MA. Neuropathological abnormalities in schizophrenia: evidence from magnetization transfer imaging. *Brain*. 2001;124(pt 5):882-892.
42. Lewis DA, Lieberman JA. Catching up on schizophrenia: natural history and neurobiology. *Neuron*. 2000;28:325-334.
43. Selemon LD, Rajkowska G, Goldman-Rakic PS. Abnormally high neuronal density in the schizophrenic cortex: a morphometric analysis of prefrontal area 9 and occipital area 17. *Arch Gen Psychiatry*. 1995;52:805-820.
44. Selemon LD, Rajkowska G, Goldman-Rakic PS. Elevated neuronal density in prefrontal area 46 in brains from schizophrenic patients: application of a three-dimensional, stereologic counting method. *J Comp Neurol*. 1998;392:402-412.
45. Selemon LD, Goldman-Rakic PS. The reduced neuropil hypothesis: a circuit based model of schizophrenia. *Biol Psychiatry*. 1999;45:17-25.
46. Jennings J, McIntosh AR, Kapur S, Zipursky RB, Houle S. Functional network differences in schizophrenia: a rCBF study of semantic processing. *Neuroreport*. 1998;9:1697-1700.
47. Heckers S, Rauch SL, Goff D, Savage CR, Schacter DL, Fischman AJ, Alpert NM. Impaired recruitment of the hippocampus during conscious recollection in schizophrenia. *Nat Neurosci*. 1998;1:318-323.
48. Manoach DS, Gollub RL, Benson ES, et al. Schizophrenic subjects show aberrant fMRI activation of dorsolateral prefrontal cortex and basal ganglia during working memory performance. *Biol Psychiatry*. 2000;48:99-109.
49. Callicott JH, Bertolino A, Mattay VS, Langheim FJ, Duyn J, Coppola R, Goldberg TE, Weinberger DR. Physiological dysfunction of the dorsolateral prefrontal cortex in schizophrenia revisited. *Cereb Cortex*. 2000;10:1078-1092.
50. Phillips ML, Williams L, Senior C, Brammer MJ, Andrew C, Williams SC, David AS. A differential neural response to threatening and non-threatening negative facial expressions in paranoid and non-paranoid schizophrenics. *Psychiatry Res*. 1999;92:11-31.
51. Russell TA, Rubia K, Bullmore ET, Soni W, Suckling J, Brammer MJ, Simmons A, Williams SC, Sharma T. Exploring the social brain in schizophrenia: left prefrontal underactivation during mental state attribution. *Am J Psychiatry*. 2000;157:2040-2042.
52. Shenton ME, Kikinis R, Jolesz FA, Pollak SD, LeMay M, Wible CG, Hokama H, Martin J, Metcalf D, Coleman M, McCarley RW. Abnormalities of the left temporal lobe and thought disorder in schizophrenia: a quantitative magnetic resonance imaging study. *N Engl J Med*. 1992;327:604-612.
53. Shapleske J, Russell SL, Chitnis XA, Suckling J, Simmons A, Bullmore ET, Woodruff PW, David AS. A computational morphometric MRI study of schizophrenia: effects of hallucinations. *Cereb Cortex*. 2002;12:1331-1341.
54. Wilke M, Kaufmann C, Grabner A, Putz B, Wetter TC, Auer DP. Gray matter changes and correlates of disease severity in schizophrenia: a statistical parametric mapping study. *Neuroimage*. 2001;13:814-824.
55. Ananth H, Popescu I, Critchley HD, Good CD, Frackowiak RS, Dolan RJ. Cortical and subcortical gray matter abnormalities in schizophrenia determined through structural magnetic resonance imaging with optimized volumetric voxel-based morphometry. *Am J Psychiatry*. 2002;159:1497-1505.
56. Job DE, Whalley HC, McConnell S, Glabus M, Johnstone EC, Lawrie SM. Structural gray matter differences between first-episode schizophrenics and normal controls using voxel-based morphometry. *Neuroimage*. 2002;17:880-889.
57. Mathalon DH, Sullivan EV, Lim KO, Pfefferbaum A. Progressive brain volume changes and the clinical course of schizophrenia in men: a longitudinal magnetic resonance imaging study. *Arch Gen Psychiatry*. 2001;58:148-157.
58. Cahn W, Pol HE, Lems EB, van Haren NE, Schnack HG, van der Linden JA, Schothorst PF, van Engeland H, Kahn RS. Brain volume changes in first-episode schizophrenia: a 1-year follow-up study. *Arch Gen Psychiatry*. 2002;59:1002-1010.